

Exame de Ecocardiografia



Nome: CINZINHA	Espécie: Canina	Raça: A. Bully
Idade: 2 meses	Sexo: M	Peso: 1,9 kg
Tutor: Alessandra Ventura		ECC: 5/9
Médico veterinário solicitante: Alessandra Ventura		Data: 19.12.2025

- Frequência cardíaca: 190 bat/min
- Ritmo: regular (sinusal)

AVALIAÇÃO BIDIMENSIONAL

- Valvas atrioventriculares:
 - Mitral: normal
 - Tricúspide: normal
- Valvas semilunares:
 - Aórtica: normal
 - Pulmonar: normal
- Pericárdio: normal
- Aorta: 10,0 mm (normal)
- Átrio esquerdo: 13,6 mm (normal)
 - Relação AE/Ao: 1,36 (normal)
- Átrio direito: normal
- Diâmetro diastólico da cavidade do ventrículo direito: 5,4 mm (normal)
- Espessura da parede livre do ventrículo direito em diástole: 2,8 mm (normal)

AVALIAÇÃO PELO MODO M

- Excursão sistólica do plano anular tricúspide (TAPSE): 8,5 mm (normal)
- Ventrículo esquerdo:
 - Septo interventricular: 4,6 mm (normal)
 - Parede livre: 4,4 mm (normal)Cavidade do VE
 - Diâmetro diastólico: 16,8 mm (normal)
 - Diâmetro sistólico: 8,5 mm (normal)
 - Fração de encurtamento: 49% (normal)
 - Fração de ejeção (método Teicholz): 84% (normal)
- Índice de distensibilidade da artéria pulmonar (ramo direito): 42% (normal)

AVALIAÇÃO DOPPLER COLORIDO

O estudo Doppler colorido evidenciou fluxos valvares dentro da normalidade.

AVALIAÇÃO DOPPLER ESPECTRAL

- Velocidade máxima do fluxo aórtico: 0,94 m/s
 - Velocidade máxima do fluxo pulmonar: 0,98 m/s
 - Velocidade onda E: 0,84 m/s
 - Velocidade onda A: 0,74 m/s
 - Relação E/A: 1,1 (normal)
 - Tempo de relaxamento isovolumétrico (TRIV): 42 ms
- Gradiente: 3,6 mmHg
Gradiente: 3,8 mmHg

AVALIAÇÃO DOPPLER TECIDUAL


Parede lateral ânulo da mitral

- Velocidade máxima onda S': 0,08 m/s
- Velocidade máxima onda E': 0,08 m/s
- Velocidade máxima onda A': 0,05 m/s

OBSERVAÇÕES: paciente calmo durante a realização do exame.

CONCLUSÃO:

Fluxos valvares normais. Câmaras e paredes cardíacas com dimensões normais. Função sistólica preservada. Função diastólica preservada.


MV, MSc, Dr Frederico Aécio C. Soares
Cardiologista Veterinário Diplomado pela SBCV
CRMV-RS 11397
(51) 985755020

VINNO6

MI -- / TI -- G3-10P Ped Cardiac

DP 9.00

HAR

AP100%

DG49%

Fq7MHz

FR58.6Hz

DR78dB

VD VE
AD AE

HR 190 bpm

19-12-2025 19:19

VINNO6

MI -- / TI -- G3-10P Ped Cardiac

DP 7.29

HAR

AP100%

DG46%

Fq7MHz

FR58.4Hz

DR78dB

PW

AP100%

DG66%

Fq5.7MHz

PRF12.4kHz

WF102.4Hz

SD2.6cm

HR 189 bpm

2.MV Vel E
3.MV Vel A

Ped Cardiac	
1 Time	42.00ms
2 MV Vel E	83.52cm/s
PG	2.79mmHg
3 MV Vel A	74.09cm/s
PG	2.20mmHg
Ped Cardiac Calculations	
MV E/A ⁰ Ratio	1.13

19-12-2025 19:20

VINNO⁶

DP 6.56

HAR

AP100%

DG48%

Fq7MHz

FR63.1Hz

DR78dB

TD

AP40%

DG46%

Fq4MHz

PRF2.1kHz

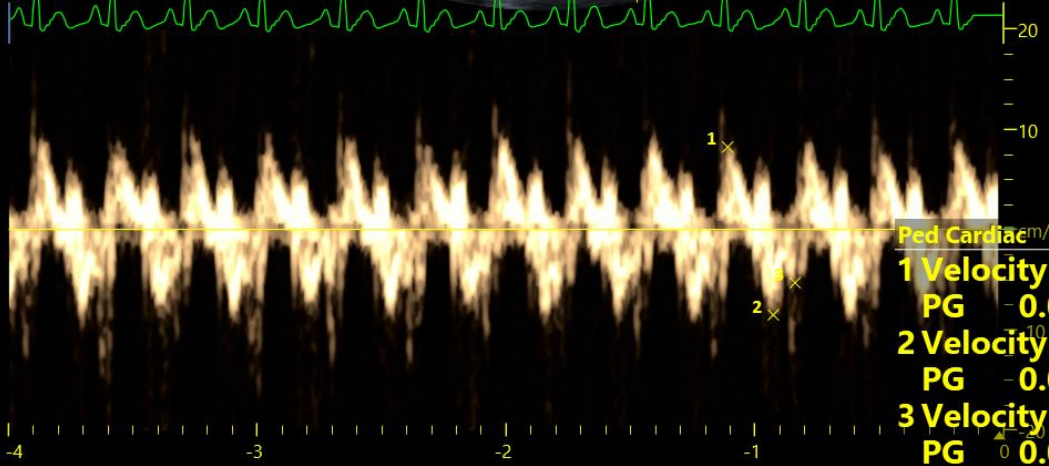
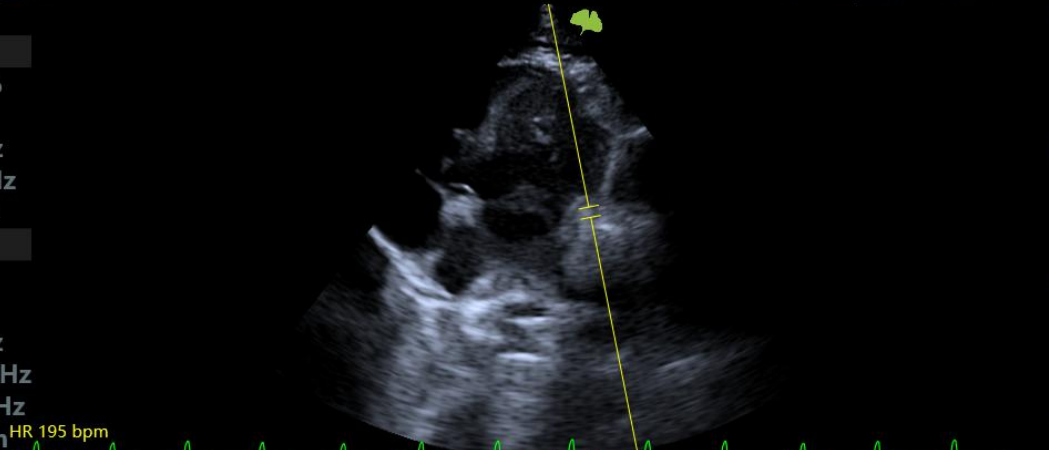
WF30.9Hz

SD3.1cm

HR 195 bpm

MI -- / TI -- G3-10P

Ped Cardiac



Ped Cardiac ^{m/s}

1 Velocity 8.32cm/s
PG - 0.03mmHg

2 Velocity 8.42cm/s
PG - 0.03mmHg

3 Velocity 5.22cm/s
PG 0.01mmHg

19-12-2025 19:20

VINNO⁶

DP 6.56

HAR

FLUXO MITRAL

AP100%

DG44%

Fq7MHz

FR17.1Hz

DR78dB

CF

AP100%

DG65%


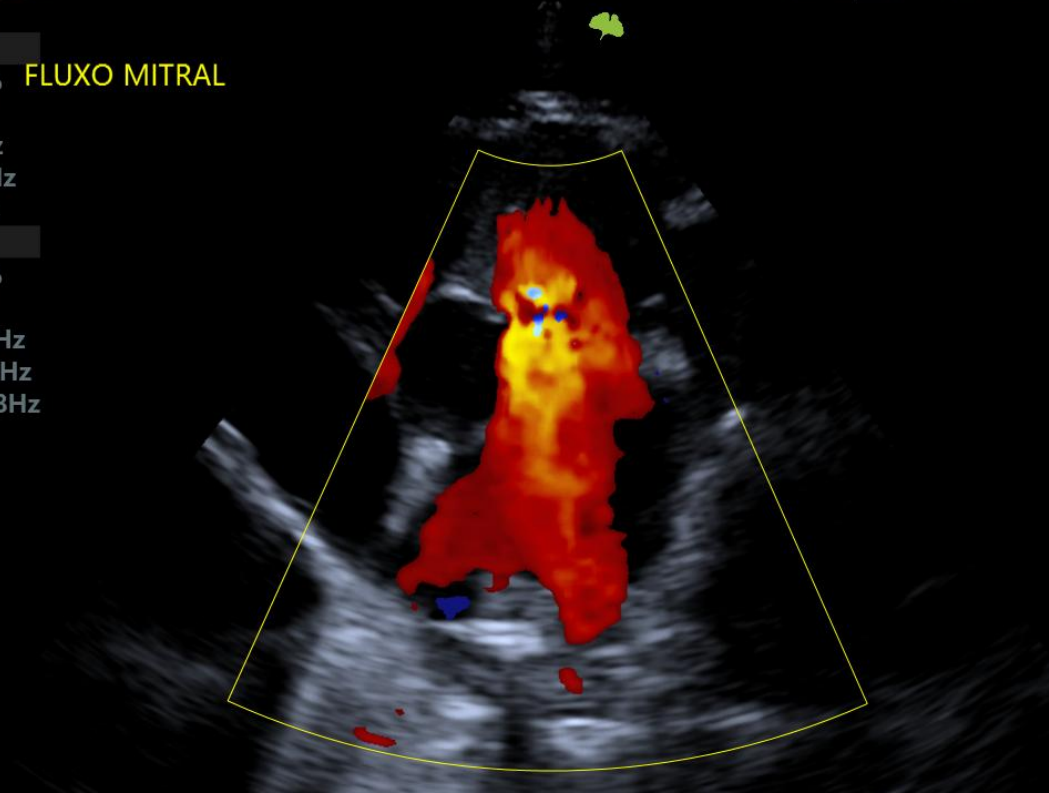
Fq3.3MHz

PRF6.0kHz

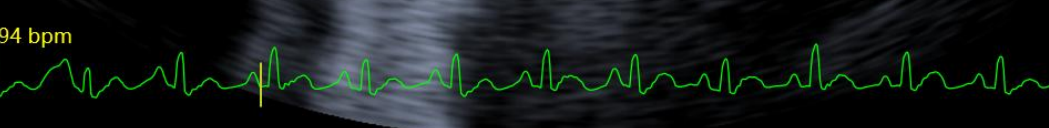
WF531.8Hz

MI -- / TI -- G3-10P

Ped Cardiac



HR 194 bpm



19-12-2025 19:21

VINNO6

MI -- / TI -- G3-10P Ped Cardiac

DP 6.56

HAR FLUXO AORTICO

AP100%

DG44%

Fq7MHz

FR22.8Hz

DR78dB

CF

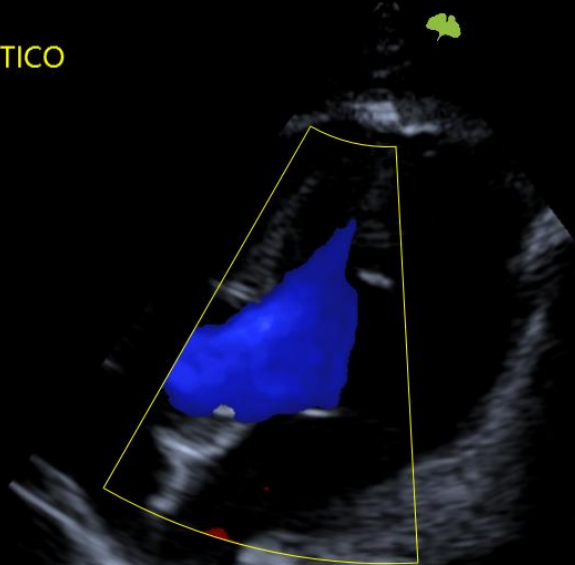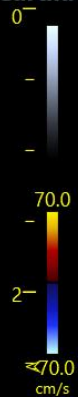AP100%

DG65%

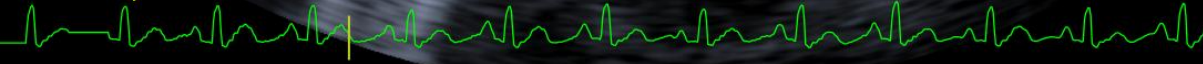Fq3.3MHz

PRF6.0kHz

WF531.8Hz



HR 197 bpm



19-12-2025 19:21

VINNO6

MI -- / TI -- G3-10P Ped Cardiac

DP 6.56

HAR

AP100%

DG44%

Fq7MHz

FR63.1Hz

DR78dB

PW

AP100%

DG66%

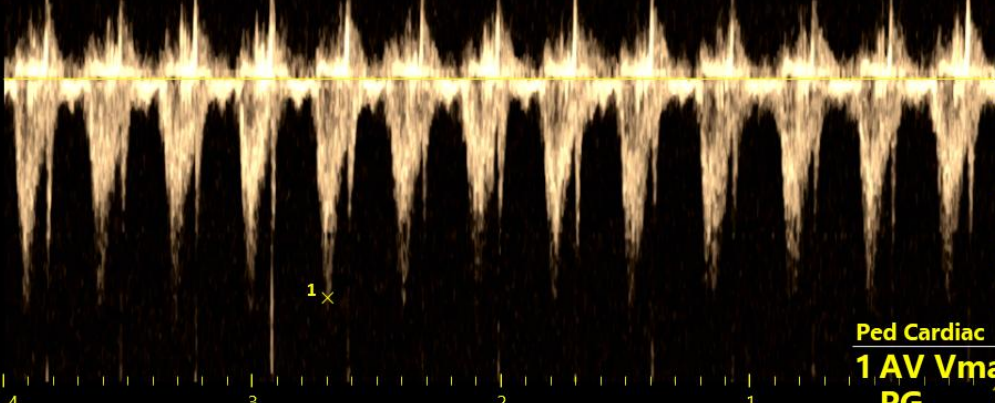
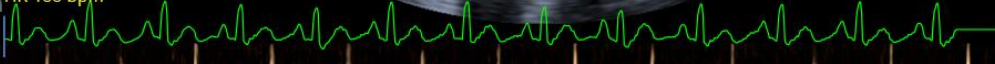
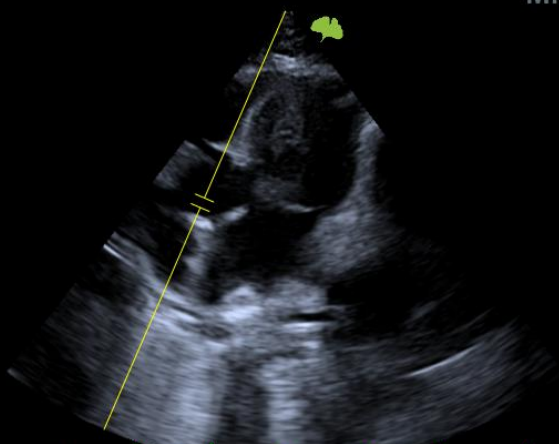

Fq5.7MHz

PRF12.4kHz

WF124.2Hz

SD3.0cm

HR 188 bpm



Ped Cardiac

1 AV Vmax94.39cm/s
PG 3.56mmHg

19-12-2025 19:22

VINNO6

DP 6.56

HAR

AP100%

DG44%

Fq7MHz

FR55.6Hz

DR78dB

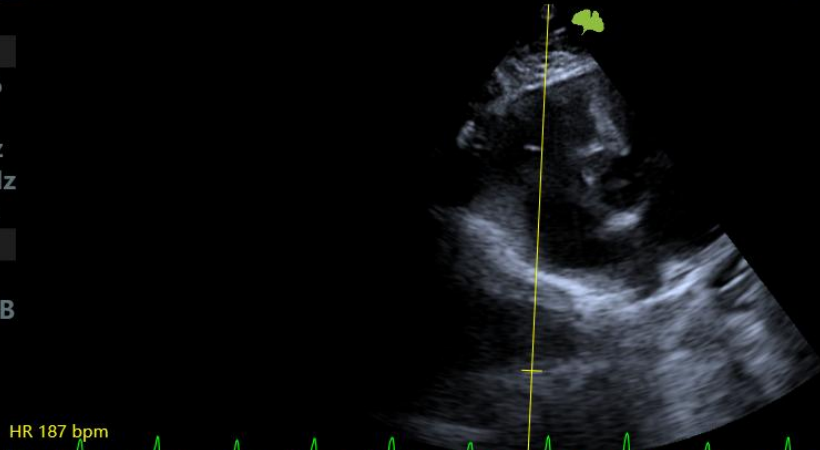
M

DG34%

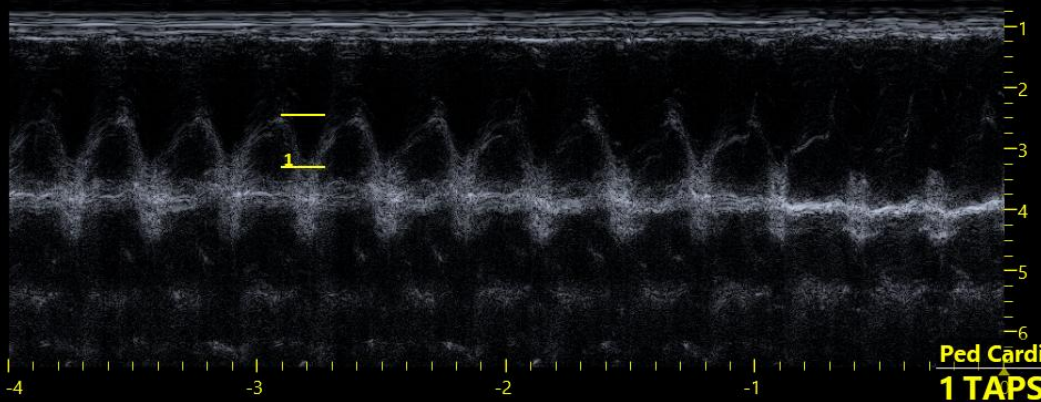
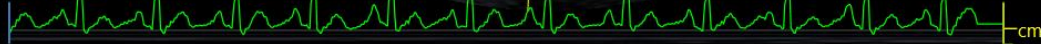
DR108dB

MI -- / TI -- G3-10P

Ped Cardiac



HR 187 bpm



Ped Cardiac
1 TAPSE 8.48mm

19-12-2025 19:22

VINNO6

DP 6.56

HAR

AP100% FLUXO TRICUSPIDE

DG44%

Fq7MHz

FR21.0Hz

DR78dB

CF

AP100%

DG65%

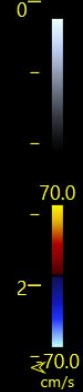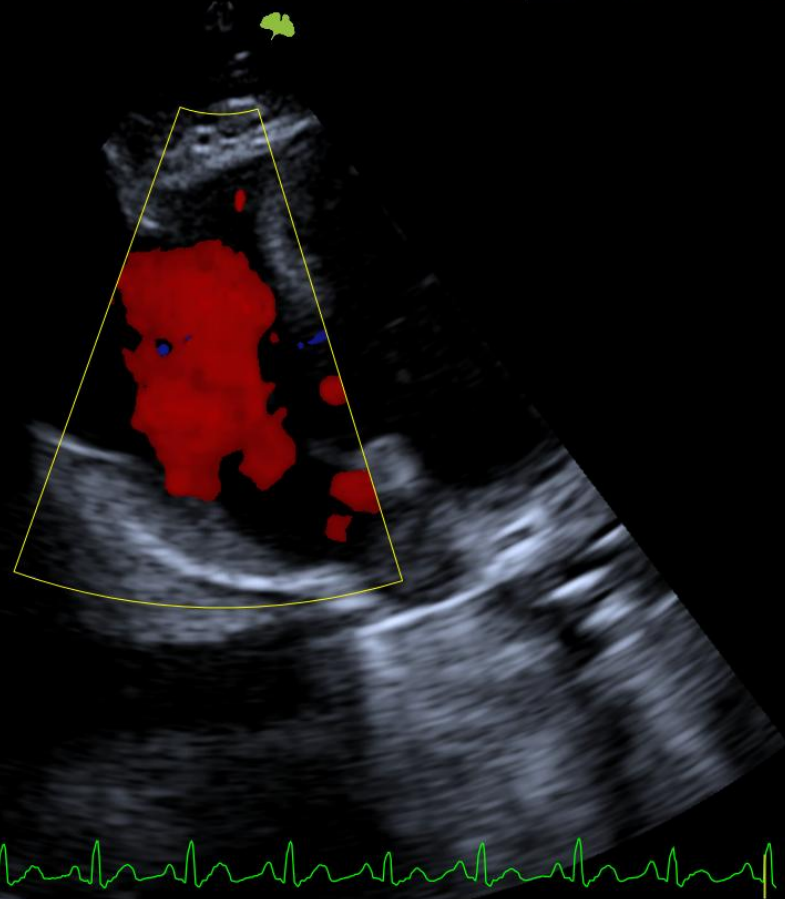
Fq3.3MHz

PRF6.0kHz

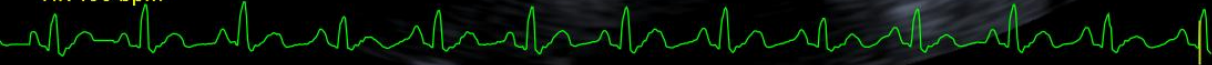WF531.8Hz

MI -- / TI -- G3-10P

Ped Cardiac



HR 190 bpm



19-12-2025 19:22

VINNO6

MI -- / TI -- G3-10P Ped Cardiac

DP 6.56

HAR FLUXO VALVA PULM

AP100%

DG44%

Fq7MHz

FR18.9Hz

DR78dB

CF

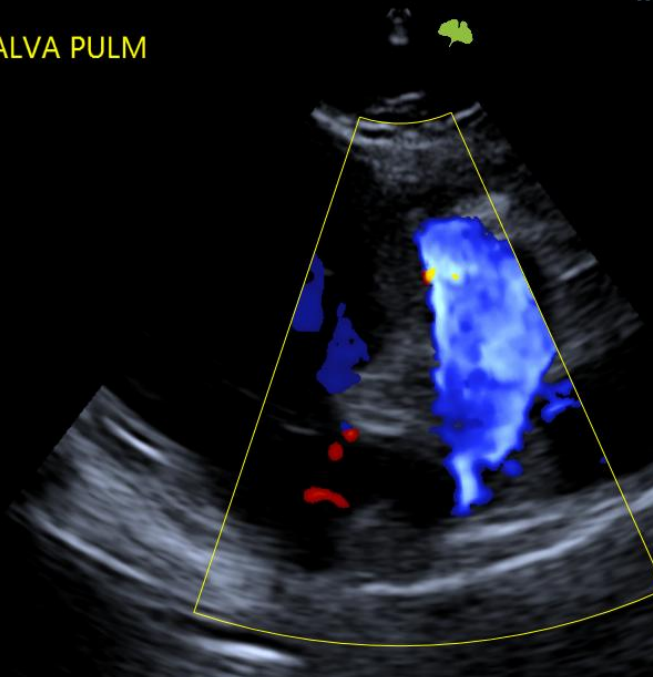
AP100%

DG65%

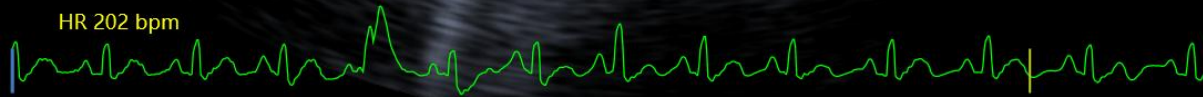
Fq3.3MHz

PRF6.0kHz

WF531.8Hz



HR 202 bpm



19-12-2025 19:23

VINNO6

MI -- / TI -- G3-10P Ped Cardiac

DP 6.56

HAR

AP100%

DG44%

Fq7MHz

FR63.1Hz

DR78dB

PW

AP100%

DG66%

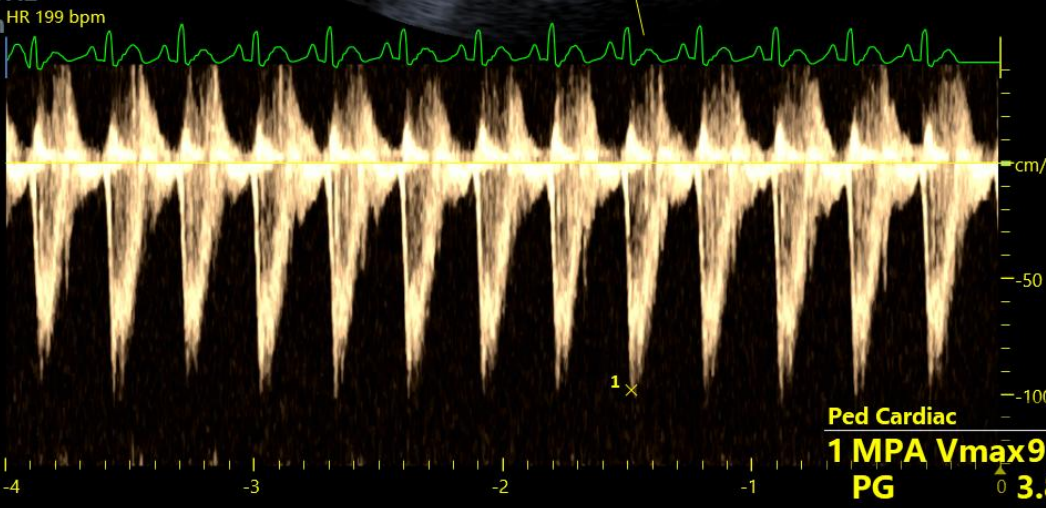
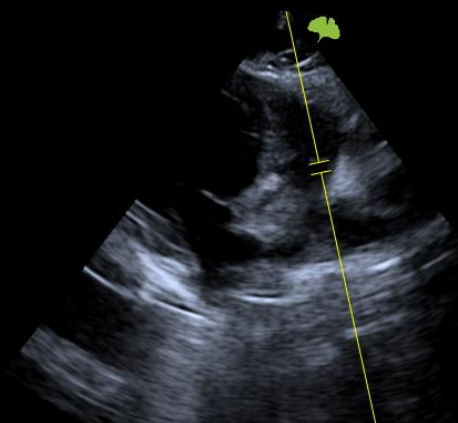
Fq5.7MHz

PRF12.4kHz

WF124.1Hz

SD2.3cm

HR 199 bpm



Ped Cardiac

1 MPA Vmax97.88cm/s
PG 3.83mmHg

19-12-2025 19:23

VINNO6

DP 6.56

HAR

AP100%

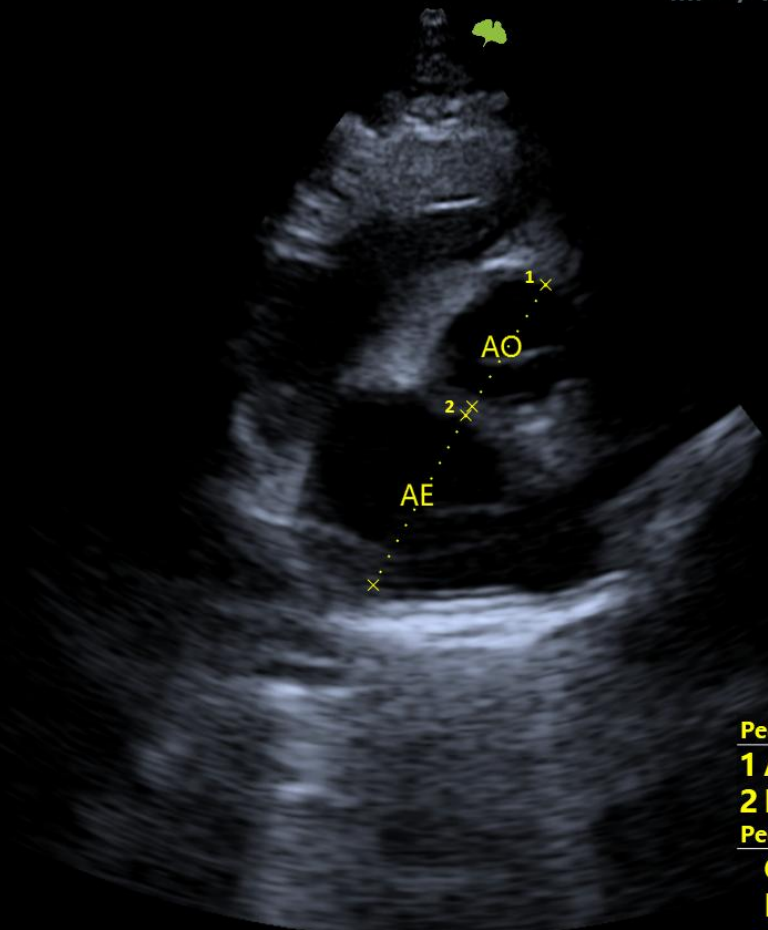
DG48%

Fq7MHz

FR63.1Hz

DR78dB

MI -- / TI -- G3-10P Ped Cardiac



Ped Cardiac

1 Ao Diam 10.03mm

2 LA Diam 13.64mm

Ped Cardiac Calculations

CSA(AV SV) 0.79cm²

LA/Ao(2D) 1.36

19-12-2025 19:24

VINNO6

DP 9.00

HAR

AP100%

DG48%

Fq7MHz

FR71.4Hz

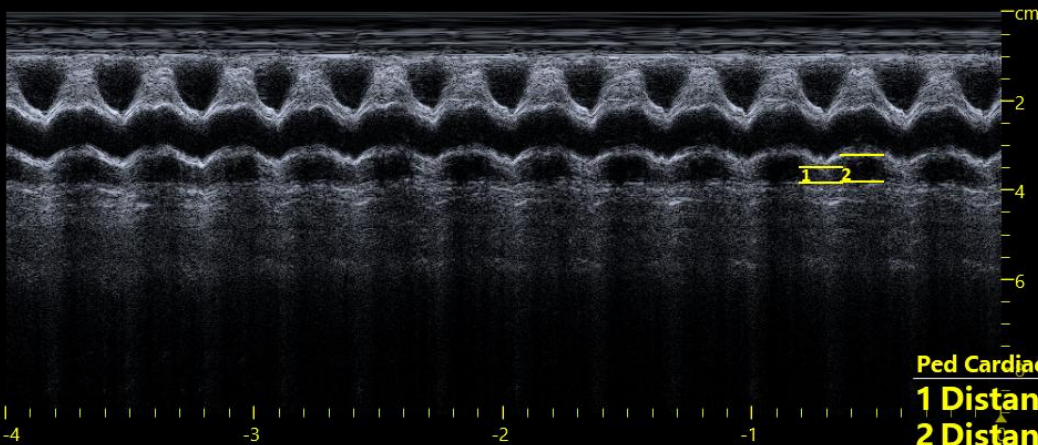
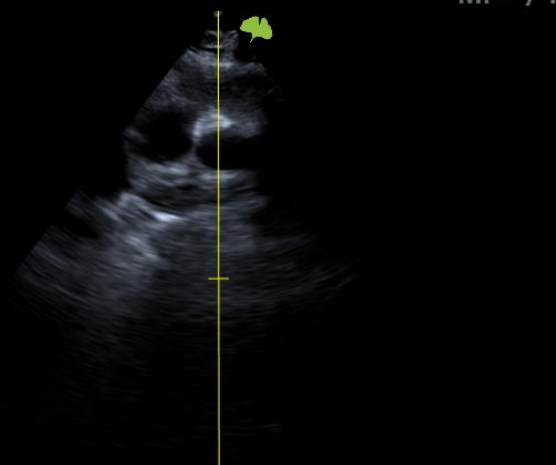
DR78dB

M

DG38%

DR108dB

MI -- / TI -- G3-10P Ped Cardiac

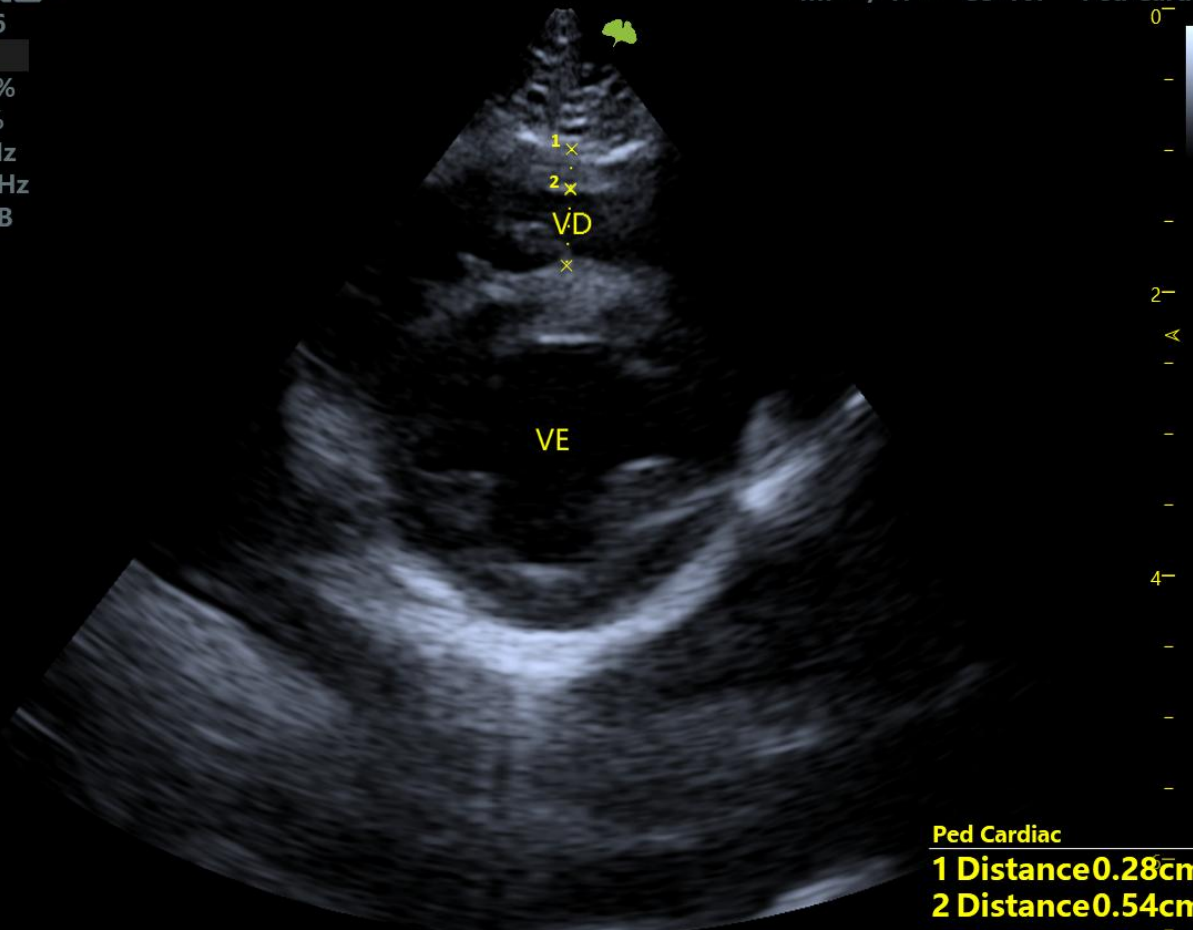


Ped Cardiac

1 Distance 0.35cm

2 Distance 0.60cm

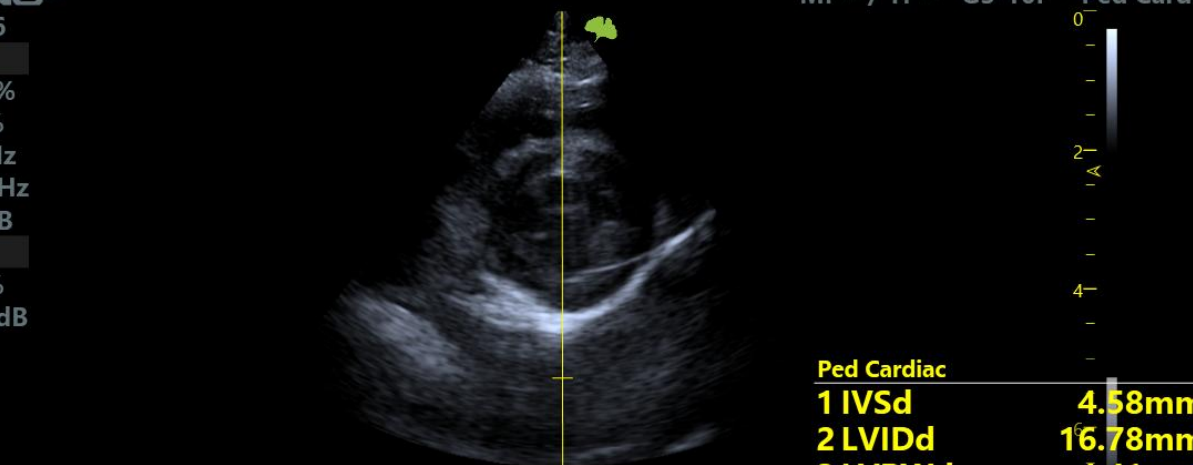
19-12-2025 19:24



Ped Cardiac

1 Distance 0.28cm
 2 Distance 0.54cm

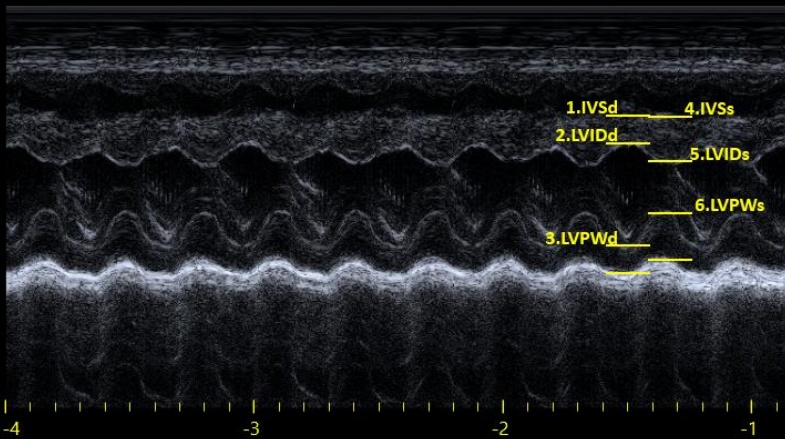
19-12-2025 19:25



Ped Cardiac

1 IVSd 4.58mm
 2 LVIDd 16.78mm
 3 LVPWd 4.41mm
 4 IVSs 7.29mm
 5 LVIDs 8.48mm
 6 LVPWs 7.63mm

Ped Cardiac Calculations
 LVEDV(M-Teich) 8.11ml
 LVESV(M-Teich) 1.31ml
 SV(M-Teich) 6.80ml
 EF(M-Teich) 83.80%
 %FS(M) 49.46%
 LVd Mass(M) -0.72g
 %IVS(M) 59.17%
 %LVPW(M) 73.02%



19-12-2025 19:25

VINNO⁶

DP 6.56

HAR

AP100%

DG48%

Fq7MHz

FR55.6Hz

DR78dB

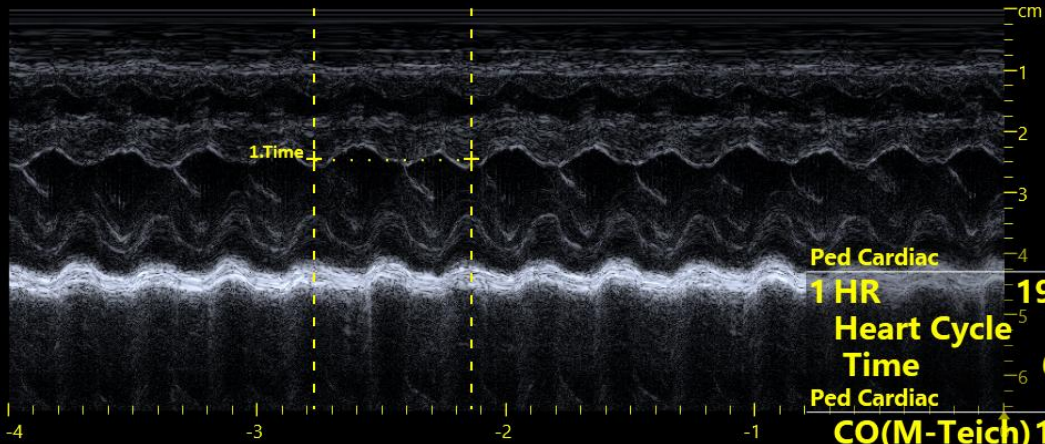
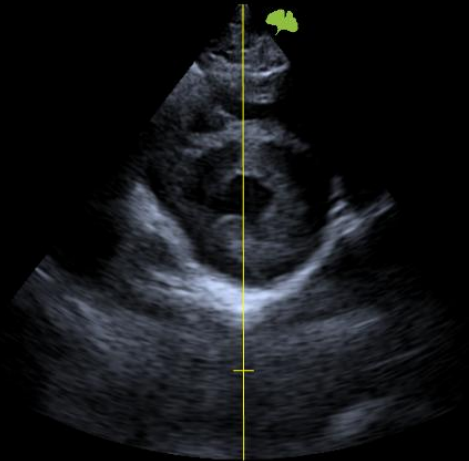
M

DG38%

DR108dB

MI -- / TI -- G3-10P

Ped Cardiac



Ped Cardiac

1 HR 190.00bpm

Heart Cycle 2.00

Time 633.00ms

Ped Cardiac Calculations

CO(M-Teich) 1.29L/min

19-12-2025 19:26

VINNO⁶

DP 6.56

HAR

AP100%

DG45%

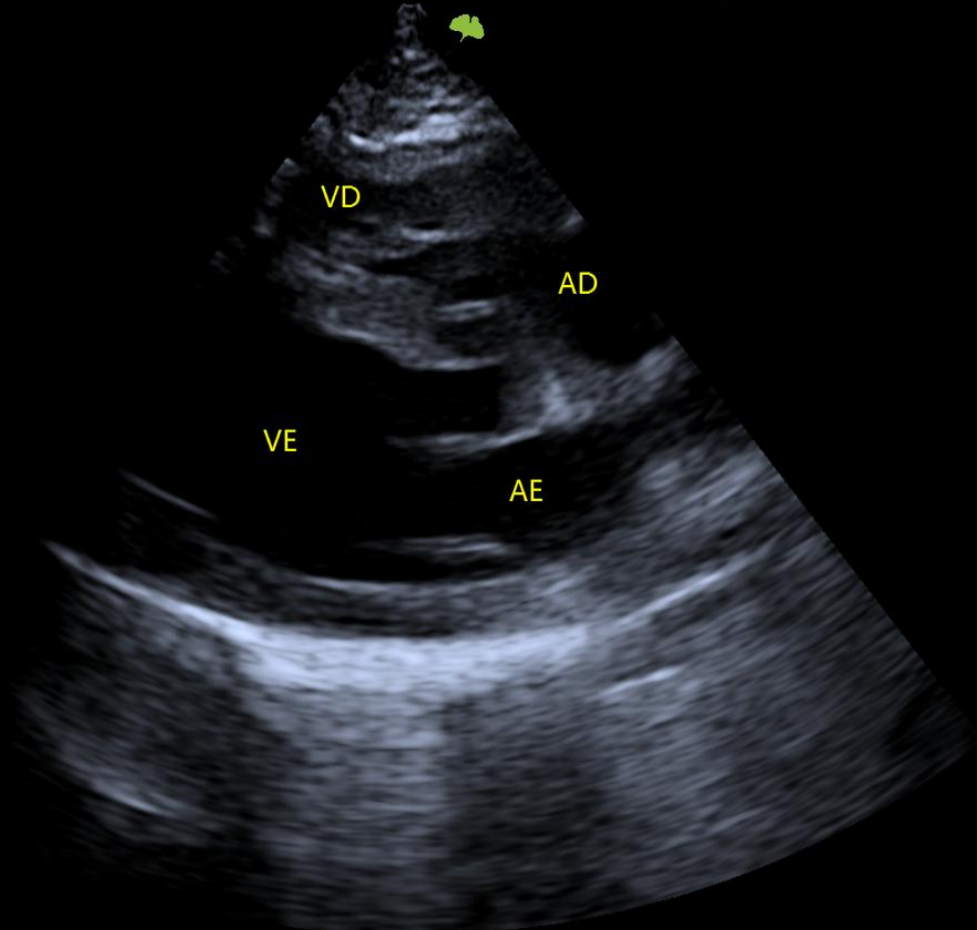
Fq7MHz

FR63.1Hz

DR78dB

MI -- / TI -- G3-10P

Ped Cardiac



19-12-2025 19:26